

Research Validates Omnilux in Professional and Home-Use Markets

By Fred Wilson and Kevin A. Wilson,
Contributing Editors

Available in the U.S. since 2003, the Omnilux (Photo Therapeutics, Inc., Carlsbad, Calif.) professional model has been the benchmark for light-emitting diode (LED) devices and the system of choice for many physicians. The device consists of a base unit, which features three distinct detachable treatment heads, 415 nm (blue), 633 nm (red) and 830 nm (infrared). Each treatment head delivers pure, non-thermal light at a proven intensity and dose. The versatility of the unit contributes to successful treatment of acne, periorbital wrinkles, muscular pain and psoriasis. It also accelerates wound healing, including the reduction of post-procedure redness and swelling.

Research Validates Omnilux

"I combine Omnilux with laser and light treatment to reduce downtime and healing time."

Dermatologist Glynis Ablon, M.D., of the Ablon Skin Institute in Manhattan Beach, Calif., has used the Omnilux for more than two years. "I run it five to ten times each day," she said. "I use it most frequently for redness and healing after treatment with my erbium laser, ProFractional device (Sciton, Inc., Palo Alto, Calif.) and my intense pulsed light (IPL) device. I combine Omnilux with laser and light treatment to reduce downtime and healing time. For example, all my patients treated with the erbium laser also receive Omnilux treatment." To reduce redness and swelling Dr. Ablon irradiates with the Omnilux red light for 5 to 20 minutes.



Glynis Ablon, M.D.
Dermatologist
Ablon Skin Institute
Manhattan Beach, CA

In addition to redness, Dr. Ablon uses the Omnilux to treat acne, psoriasis, precancerous lesions, basal cell carcinoma (BCC) and vitiligo. "I've had good results with all these conditions," she noted. "I've also used the Omnilux to treat the facial flushing of rosacea."

Some of Dr. Ablon's patients have severe cystic acne and others don't want to or can't take Accutane (Roche U.S., Nutley, N.J.). "With the Omnilux I get dramatic decreases in the size and number of cysts," Dr. Ablon said.

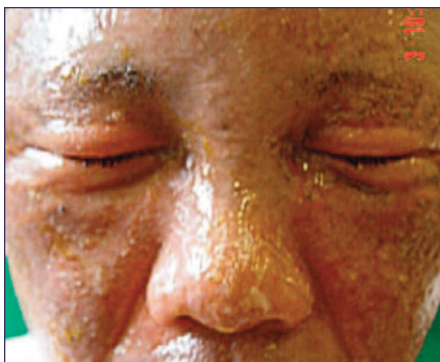Before purchasing the Omnilux Dr. Ablon had treated acne and actinic keratosis with photodynamic therapy using Levulan (DUSA Pharmaceuticals, Wilmington, Mass.) and blue light. "The blue light device I used was awkward for patients because they had to sit upright during treatment," she said. "I knew that Omnilux had a blue light treatment head, so when I saw the red and infrared options I decided to purchase the Omnilux Revive with red light and the Omnilux Plus with near infrared light as well. Now, during

Omnilux treatment, patients lie down and are much more comfortable. Furthermore, with Omnilux we have the ability to deliver light only treatments for acne which is beneficial since we don't run any risk of post treatment complications."

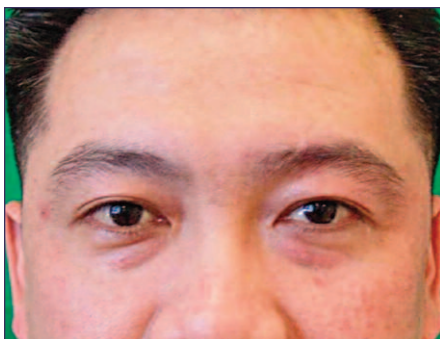
For BCC, Dr. Ablon uses photodynamic therapy with Levulan. "For a patient with BCC on her arms, I paint the entire arm with Levulan and after incubation, I use Omnilux to activate the protoporphyrin IX. A follow-up biopsy one month after a single treatment showed no tumors at the site." Dr. Ablon has observed no complications after Omnilux treatment and said that patients are very happy with their results.

"Psoriasis is particularly exciting," Dr. Ablon said. "We've seen a number of patients respond well to the combination of red and near infrared light, especially in hard-to-treat areas. In particular, we had a 58 year old man with plaque psoriasis on the mid back, who had not responded to routine treatment. After a five week course of alternate infrared and red light, the patient had achieved 90% clearance of his psoriatic plaques and maintained this clearance level for 11 months. I have also seen this combination of wavelengths work exceptionally well with Taclonex q (Warner Chilcott, Rockaway, N.J.) and Tazorac 0.05% gel (Allergan, Inc., Irvine, Calif.). Another psoriatic patient who failed with methotrexate responded with 100% clearance of plaques on the right anterior shin after five weeks of therapy and has remained clear for the last eight months."

Although Dr. Ablon has standard protocols for treating each condition, she varies the protocol on the basis of what each patient needs and what she knows each wavelength does. "For acne we typically alternate red and blue light whereas we use the red and infrared lights for photorejuvenation," she said. "If a patient has extremely red, cystic acne I may, instead of alternating red and blue light, treat twice with red light, once with blue, twice again with red, and once again

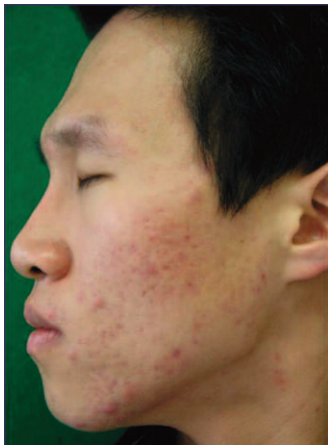

39 year old male patient with electrical spark burn injury to the face, before Tx

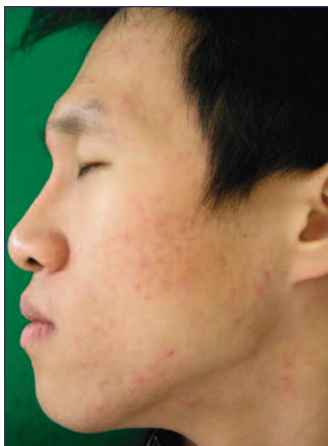

Three months after near infrared and red Omnilux LED therapy

Photos courtesy of Professor Jin-wang Kim, M.D., Ph.D.



Before Tx



Eight weeks after combination Omnilux Blue and Omnilux Revive treatments

“We have two Omnilux devices, each in a separate room. Both devices are very busy.”

with blue, in that order. Or I might treat three times with red light and once with blue.” Dr. Ablon averages eight sessions per patient, but she often suggests several additional visits if she believes a patient needs it. “I stop when I feel the patient is stable and recommend a maintenance session once a month or if the patient has a flare-up,” she said. “Patients are extremely satisfied with our protocols. And some insurance companies are paying for light treatment of acne or pre-cancerous lesions.”

Dr. Ablon had no difficulty adding the Omnilux to her practice. “It has been easy to integrate because it’s mobile and can be moved from room to room,” she said.

Leonardo Rasi, M.D., a general and cosmetic surgeon practicing at Senza Medical Corporation in Redlands, Calif., uses the Omnilux Revive and the Omnilux Plus for photorejuvenation and to help healing after a procedure. “I often use the Omnilux Plus for ten minutes before and the Omnilux Revive for ten minutes after the Fraxel (Reliant Technologies, Mountain View, Calif.) procedure to reduce tenderness, redness and swelling,” he noted. “Patients for skin rejuvenation come in twice a week for eight sessions. I don’t use the blue light because I don’t treat many acne patients. We have two Omnilux devices, each in a separate room. Both devices are very busy.”



Leonardo Rasi, M.D.
General and Cosmetic Surgeon
Senza Medical Corporation
Redlands, CA

Dr. Rasi was attracted to the Omnilux for two reasons, “Photo Therapeutics has done most of the research on LEDs and the treatment procedure for light only therapy is passive therefore it doesn’t require the constant attention of a staff member,” he said. “The patient is simply placed under the light for a certain period and there’s no

danger. That’s a big plus for a busy practice such as ours.”

According to Dr. Rasi, the Omnilux is very easy to integrate into a practice. “The main thing is introducing the patients to it,” he said. “We’ve done specials to generate interest and the patients love it. Some try to get in more often than what the protocol calls for because they like the results and they want more. Within a few weeks they notice the improved skin texture and the glow to their skin. Improvements in lines are gradual, since we’re stimulating the natural synthesis of collagen. The procedure has been very popular.”

Neil Sadick, M.D., has found the Omnilux helpful in treating acne with the Omnilux blue and red light or blue light combined with Levulan in photodynamic therapy. “It’s good for freezing active lesions,” Dr. Sadick said. “We’ve had nice results when using the red light to decrease inflammation associated with acne, wound healing, laser resurfacing or other procedures that make the skin red.” Dr. Sadick, who practices at Sadick Dermatology in New York, N.Y., treats actinic keratosis and diffuse sun damage with photodynamic therapy using Levulan and Omnilux Blue.



Neil Sadick, M.D.
Sadick Dermatology
New York, NY

According to Dr. Sadick, the Omnilux was easy to integrate into his practice because the treatment is very safe and patients have no downtime. “We wanted an effective treatment for acne and a device gentle enough for our aestheticians to operate. For acne we give eight treatments alternating blue and red light to kill bacteria and decrease inflammation. We may do photodynamic therapy once a month if the patient needs a booster. For diffuse actinic keratosis we do two to three sessions and

for wound healing we treat twice a week with red light for three to four weeks," Dr. Sadick noted. "Omnilux has been very successful and quite popular with patients. Patients ask for it by name now."

Suzanne Bruce, M.D., a dermatologist in private practice in Houston, Texas, has used the Omnilux for approximately six months. "The Omnilux is non-invasive and has no downtime and patients have no pain during treatment," she said.



Suzanne Bruce, M.D.
Dermatologist
Houston, TX

Omnilux has been simple to integrate into Dr. Bruce's practice. "We use the Omnilux Revive, Omnilux Blue and Omnilux Plus treatment heads and our patients are very satisfied with their results," she said. "I'm considering the purchase of a second Omnilux because our current device is in almost constant use due to referrals from the patients we've treated." Dr. Bruce considers her Omnilux an anti-aging option for people who are hesitant towards more aggressive treatments such as laser resurfacing. "Omnilux gives these patients an entry point to treatments without having to worry about pain, downtime or adverse effects," she said.

Dr. Bruce uses Omnilux for acne, actinic keratosis and photorejuvenation; to speed healing after Fraxel treatment; and to reduce bruising or swelling after dermal filler injections. "For Fraxel treated patients, I use the Omnilux about 20 minutes after treatment," she said. "I alternate infrared and red light (two sessions total) for the occasional patient distressed by bruising after filler injections and for patients who get more redness or swelling than expected after treatment with intense pulsed light. I use Photo Therapeutics' recommended protocols and I've been very successful."

Shino Bay Aguilera, M.D., a dermatologist at Shino Bay Cosmetic Dermatology in Fort Lauderdale, Fla., easily integrated the Omnilux into his practice. "I wanted a device that would activate Levulan in photodynamic therapy," he said. "When I use the Omnilux to treat actinic keratosis and for photorejuvenation, the skin gets rejuvenated and the texture is better. The Omnilux definitely gets rid of actinic keratosis." Dr. Aguilera has also used the Omnilux to treat acne in a few patients. "I used the red and blue light and achieved great results," he said. "I have protocols for photodynamic therapy. I leave Levulan in contact with skin for one hour on the face, three hours on the chest, and sometimes overnight on the arms. The patient is under the blue light for 20 minutes."

Dr. Aguilera has also treated patients with the Omnilux red light to help with healing after laser irradiation. "The patients said their discomfort was reduced. I don't perform procedures with downtime so my use of the Omnilux as an adjunctive healing treatment is limited."

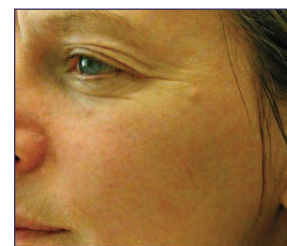Dr. Bruce envisions a very positive future for Omnilux. "I'm a huge fan of it," she said. "Although, I haven't followed patients long enough to see if their conditions continue to improve or if they reach a plateau with continued treatment, I have patients who have completed their first course of treatment and have signed up for their second course."

Dr. Ablon hopes that Photo Therapeutics will develop a device that allows her to cover larger areas during a treatment session. "I use the Omnilux to treat acne on the chest and back as well as on the face," she said. "I also use it for photorejuvenation in patients who can't afford treatment with a laser. Although it doesn't give the same results as laser ablation, our before and after patient photographs with the Omnilux show improvement in pigmentation, redness, vascularity, skin tightness and skin smoothness, without the downtime associated with laser treatments."

"Omnilux has been very successful and quite popular with patients. Patients ask for it by name now."



Before Tx



12 weeks after combination Omnilux Revive and Omnilux Plus treatments

“Our before and after patient photographs with the Omnilux show improvement in pigmentation, redness, vascularity, skin tightness and skin smoothness, without the downtime associated with laser treatments.”

Asian Skin Tx

Omnilux has also proven successful in the treatment of Asian skin types, according to published research. Two recent studies have been conducted by investigators at the National Medical Center in Seoul, Korea. In the first study, patients of skin type IV with mild-to-moderately severe acne vulgaris were treated twice weekly for four weeks, alternating the 415 nm blue and 633 nm red light alone. Follow-up assessments were performed two, four and eight weeks after the final treatment session. Results were evaluated using a comparison of clinical photographs by blinded independent dermatologists; lesion counts; subjective patient appraisals; and objective instrumental measurements of skin moisture, sebum and melanin levels. The average clearance of inflammatory lesions was 78% at the eight week assessment versus 32% to 72% obtained by photodynamic therapy. More than 75% of patients reported good to excellent results.

In the second study published in the July 2007 issue of *Journal of Photochemistry and Photobiology*, the efficacy of LED therapy on Asian skin was investigated.

For this double-blind study 76 patients, divided into three groups, underwent half face LED treatments with Omnilux Plus (830 nm) alone, Omnilux Revive (633 nm) alone and a combination of Plus and Revive, twice per week for four weeks. A specially designed mask prevented LED light from irradiating the control side of the face. A fourth group received mock irradiation on half of their face, using the stand-by mode of the 633 nm lamp.

In addition to clinical photography and patient personal assessment, subjective profilometry for periorbital wrinkles as well as gross skin elasticity and melanin levels, were measured. Biopsies of 1 mm were taken from representative volunteers on both the treated and control sides of the face and investigated using standard histological staining for collagen and elastin. Also investigated, were ultra structural

changes of the skin with transmission electron microscopy (TEM), the alteration in the status of matrix metalloproteinases (MMPs) and their tissue inhibitors (TIMPs) and changes in the levels of key cytokines using, where appropriate, immunohistochemistry, and real time reverse transcriptase-polymerase chain reaction (RT-PCR). An independent and blinded pathologist reviewed the specimens.

Results showed statistically significant subjective improvement in all treated groups compared to the mock irradiated control group, with very high satisfaction indices (SI) for the treated groups. The SI's of all treated groups continued to rise steadily following the final treatment session in all of the post treatment assessments, reaching 70% for the 633 nm only group and over 90% for both the 830 nm and the 830 nm plus 633 nm groups respectively. A very low SI of around 7% was seen for the mock group. These subjective findings were backed up by the objective profilometry, which demonstrated a statistically significant decrease in all three of the treatment groups.

Statistical analysis revealed a significant decrease in skin roughness and wrinkles at 12 weeks, and an improvement in gross elasticity on the treated sides of the patients, in all three groups. There was no significant serial change found in the control group. An evening of pigmentation was reported in subjects, which was supported by Mexameter™ readings. Conventional staining of specimens taken two weeks after the final treatment session showed much denser and thicker collagen bundles in all treated groups, compared with the mock control group. The same held true for elastinogenesis, with viable elastin fibers more numerous in all treated groups. Two weeks after the final treatment transmission electron microscopy revealed many active, fibroplastic fibroblasts surrounded by well-organized plump collagen fibers in treated specimens from all groups.

Conversely, fibroblasts from the control group and from the untreated side in the treated

groups were comparatively inactive, thin and spindle-shaped, with poorly organized collagen fibers in bundles, which were noticeably thinner than those in the treated specimens. PCR indicated significant increase in cytokines (chemical messengers), which are essential in amplifying the inflammatory response. Increases in interleukin (IL) -1b, IL-6 and tumour necrosis factor (TNF) – alpha, support earlier work by Takezaki S, 2006 (which additionally demonstrated fibroplastic changes in fibroblasts and dramatically elevated levels of both Th-1 and particularly Th-2 Tcells).

The authors concluded that the Omnilux LED therapy was effective in improving the visible signs of photo-aged skin both clinically and histologically.

Home-Use Market

After almost two years of development and research, this year will see yet another milestone in the development of light therapy with Photo Therapeutics' launch of home-use LED systems for acne and skin rejuvenation. Omnilux Clear-U and New-U, the hand held equivalents of the Omnilux professional model are designed for the self treatment of acne and for skin rejuvenation, respectively.

According to Dr. Sadick, who has conducted trials of the Omnilux Clear-U and New-U, "Such devices will increase the

use of our in-office devices because patients who use the at-home devices will want even better results available only at the doctor's office." These recent clinical studies have demonstrated high patient satisfaction and ease of use, with 70% of acne lesions clearing after four weeks of alternate blue and red light therapy and over 70% of subjects reporting visible changes in fine lines and wrinkles after four weeks of alternate red and near infrared light therapy.

Sue D'Arcy, CEO of Photo Therapeutics, Inc., is excited by the innovative steps the company has taken into the home-use market. "Physicians will now be able to recommend, not only cosmeceuticals as a home maintenance program, but also a quality light product proven and supported by robust clinical data," she said. "We certainly do not foresee these products replacing the Omnilux Professional system or routine visits to a physician, but rather as an adjunctive therapy included in one's daily skincare regimen."

"Omnilux Clear-U and New-U will increase the use of our in-office devices because patients who use the at-home devices will want even better results available only at the doctor's office."



Omnilux New-U

References:

- Goldberg DJ, Russell BA. Combination blue (415 nm) and red (633 nm) LED phototherapy in the treatment of mild to severe acne vulgaris. *J Cosmet Laser Ther.* 2006 Jun;8(2):71-75.
- Tremblay JF, Sire DJ, Lowe NJ, Moy RL. Light-emitting diode 415 nm in the treatment of inflammatory acne: an open-label, multicentric, pilot investigation. *J Cosmet Laser Ther.* 2006 Apr;8(1):31-33.
- Kim J-W, Lee J-O, Calderhead G. Clinical trial of non thermal 633 nm Omnilux LED array for renewal of photo-aging: clinical surface profilometric results. *J Korean Soc Laser Med Surg.* 2005; 9 (1): 69-76.
- Russell BA, Kellett N, Reilly LR. A study to determine the efficacy of combination LED light therapy (633 nm and 830 nm) in facial skin rejuvenation. *J Cosmet Laser Ther.* 2005 Dec;7(3-4):196-200.
- Bhat J, Birch J, Whitehurst C, Lanigan SW. A single-blinded randomized controlled study to determine the efficacy of Omnilux Revive facial treatment in skin rejuvenation. *Lasers Med Sci.* 2005;20(1):6-10. Epub 2005 May 21.
- Trelles MA, Allones I. Red light-emitting diode (LED) therapy accelerates wound healing post-blepharoplasty and periocular laser ablative resurfacing. *J Cosmet Laser Ther.* 2006 Apr;8(1):39-42.
- Morton CA, Whitehurst C, Moore JV, MacKie RM. Comparison of red and green light in the treatment of Bowen's disease by photodynamic therapy. *Br J Dermatol.* 2000 Oct;143(4):767-772.
- Lee SY, Park KH, Choi JW, *et al.* A prospective, randomized, placebo-controlled, double-blinded, and split-face clinical study on LED phototherapy for skin rejuvenation: clinical, profilometric, histologic, ultrastructural, and biochemical evaluations and comparison of three different treatment settings. *J Photochem Photobiol B.* 2007 Jul 27;88(1):51-67. Epub 2007 May 1.